

CASE STUDY



DEMOGRAPHICS

MALE
14 YEARS OLD

DIAGNOSIS

CLASS II
CROWDING & SPACING
DEEP BITE
EXCESSIVE OVERJET
MIDLINE DISCREPANCY
(LOWER 2MM TO LEFT)

MECHANICS

CARRIERE® MOTION™
INVISALIGN®
36 TOTAL ALIGNERS
NO REFINEMENT
7 DAY ALIGNER CHANGE

TREATMENT TIME

PROJECTED TREATMENT TIME:
18 MONTHS

ACTUAL TREATMENT TIME WITH
ACCELEDENT:
10.5 MONTHS

“I truly believe that AcceleDent increased the patient’s compliance with the trays knowing that he would be done with treatment sooner.”

- Dr. Paul O’Grady

CASE STUDY



DEMOGRAPHICS

MALE
14 YEARS OLD

DIAGNOSIS

CLASS II
CROWDING & SPACING
DEEP BITE
EXCESSIVE OVERJET
MIDLINE DISCREPANCY
(LOWER 2MM TO LEFT)

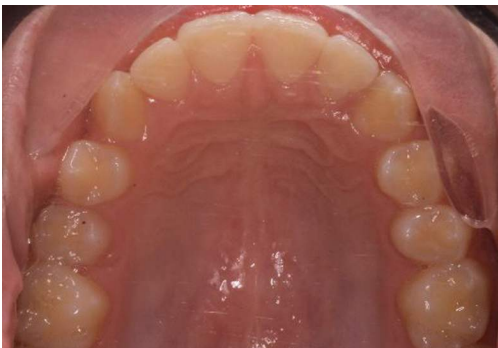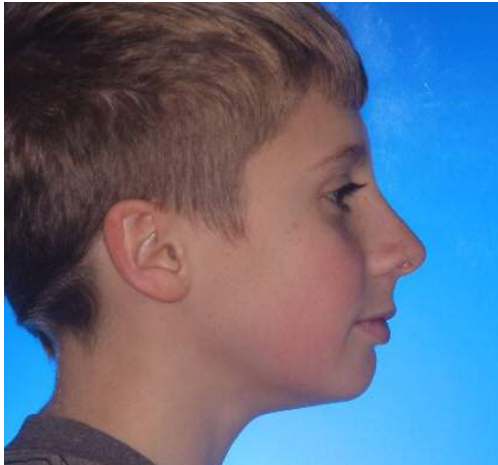MECHANICS

CARRIERE® MOTION™
INVISALIGN®
36 TOTAL ALIGNERS
NO REFINEMENT
7 DAY ALIGNER CHANGE

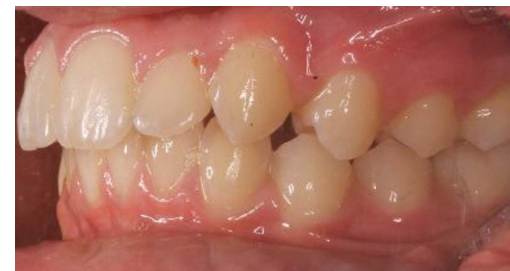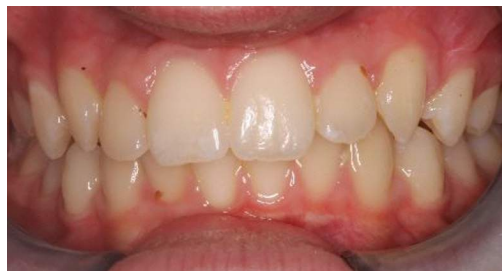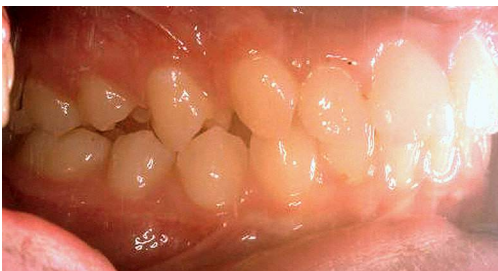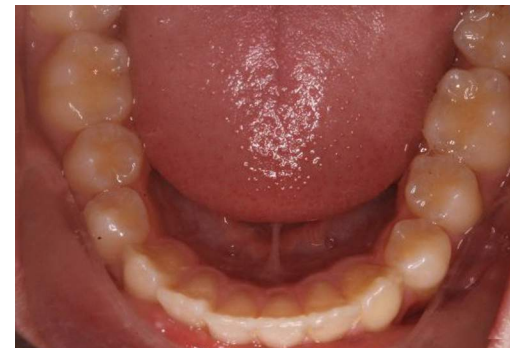TREATMENT TIME

PROJECTED TREATMENT
TIME:
18 MONTHS

ACTUAL TREATMENT
TIME WITH ACCELENT:
10.5 MONTHS



BASELINE
CHIEF CONCERN: "Bite is off"
A Carriere® Motion™ appliance was used for Class II correction prior to Invisalign treatment.



CASE STUDY



DEMOGRAPHICS

MALE
14 YEARS OLD

DIAGNOSIS

CLASS II
CROWDING & SPACING
DEEP BITE
EXCESSIVE OVERJET
MIDLINE DISCREPANCY
(LOWER 2MM TO LEFT)

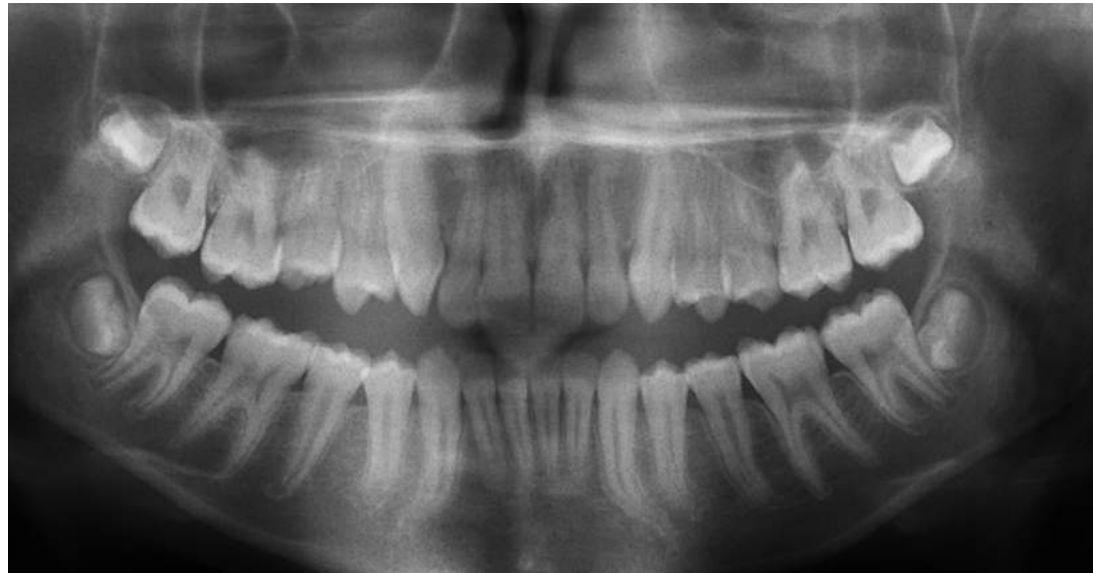
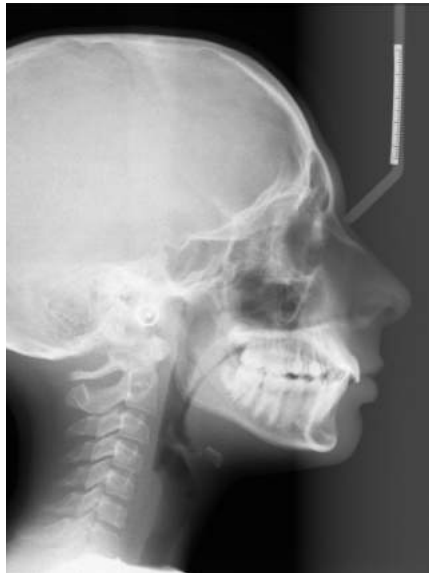MECHANICS

CARRIERE® MOTION™
INVISALIGN®
36 TOTAL ALIGNERS
NO REFINEMENT
7 DAY ALIGNER CHANGE

TREATMENT TIME

PROJECTED TREATMENT
TIME:
18 MONTHS

ACTUAL TREATMENT
TIME WITH ACCELEDDENT:
10.5 MONTHS



BASELINE

CASE STUDY



DEMOGRAPHICS

MALE
14 YEARS OLD

DIAGNOSIS

CLASS II
CROWDING & SPACING
DEEP BITE
EXCESSIVE OVERJET
MIDLINE DISCREPANCY
(LOWER 2MM TO LEFT)

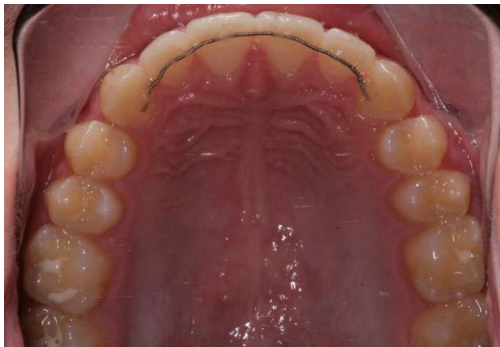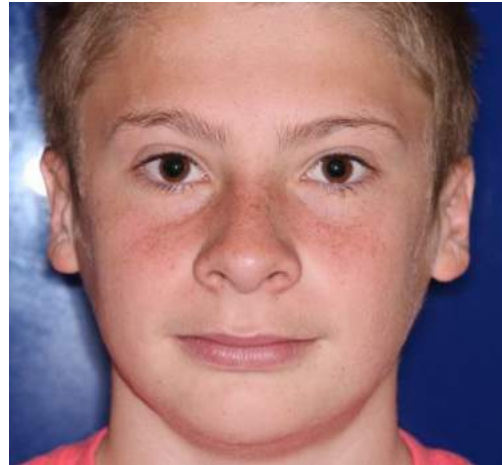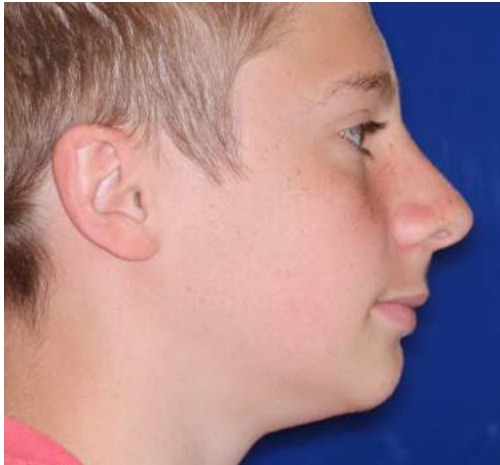MECHANICS

CARRIERE® MOTION™
INVISALIGN®
36 TOTAL ALIGNERS
NO REFINEMENT
7 DAY ALIGNER CHANGE

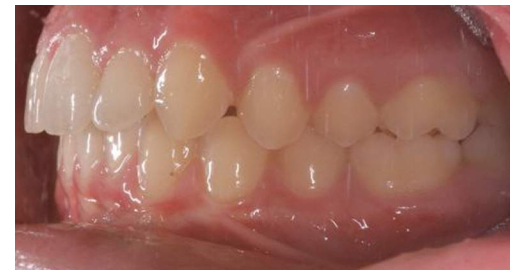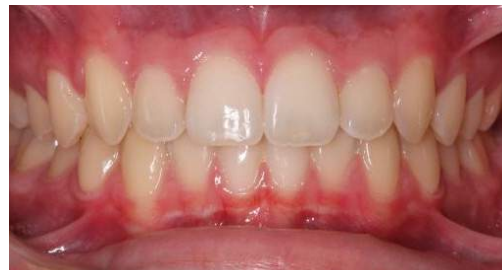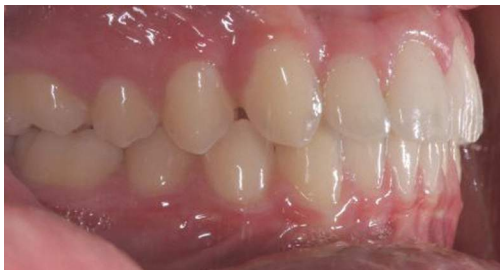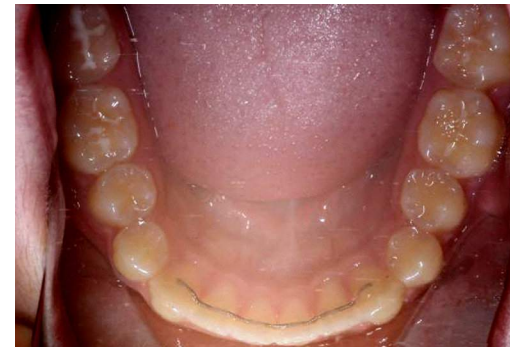TREATMENT TIME

PROJECTED TREATMENT
TIME:
18 MONTHS

ACTUAL TREATMENT
TIME WITH ACCELEDENT:
10.5 MONTHS



FINISH



CASE STUDY



DEMOGRAPHICS

MALE
14 YEARS OLD

DIAGNOSIS

CLASS II
CROWDING & SPACING
DEEP BITE
EXCESSIVE OVERJET
MIDLINE DISCREPANCY
(LOWER 2MM TO LEFT)

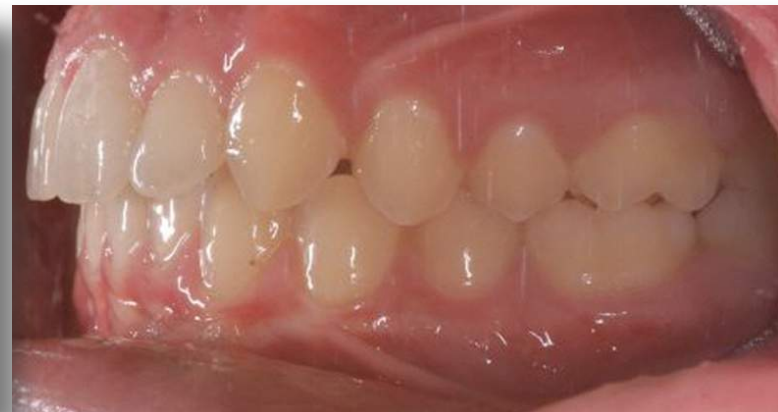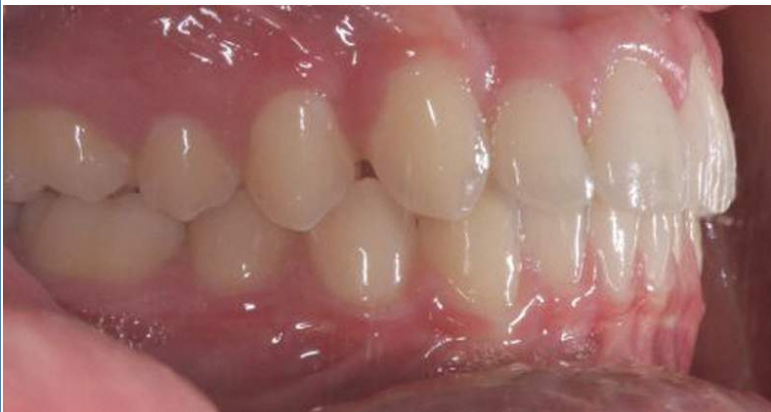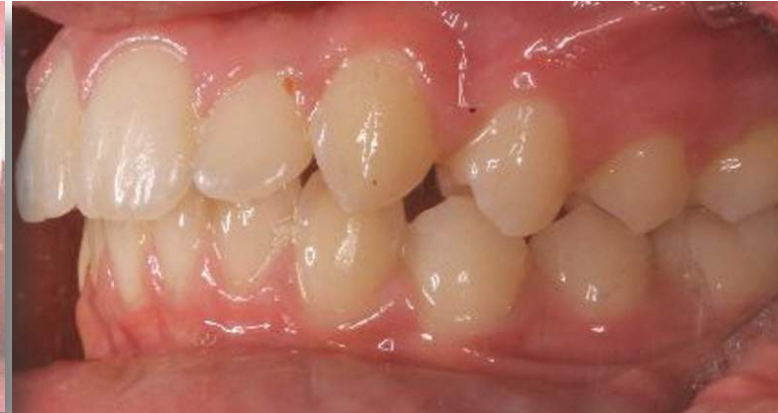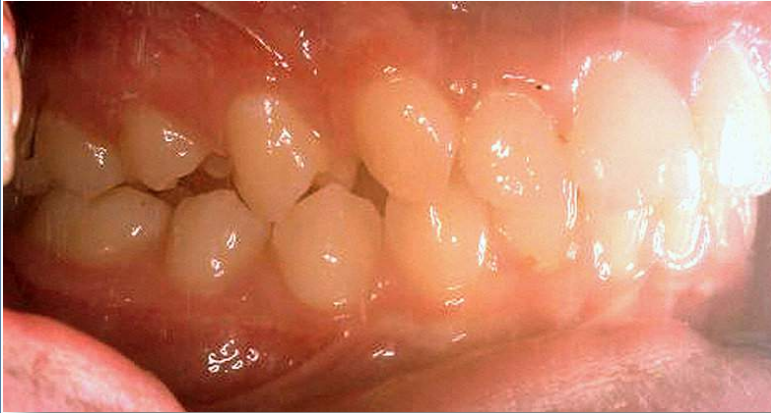MECHANICS

CARRIERE® MOTION™
INVISALIGN®
36 TOTAL ALIGNERS
NO REFINEMENT
7 DAY ALIGNER CHANGE

TREATMENT TIME

PROJECTED TREATMENT
TIME:
18 MONTHS

ACTUAL TREATMENT
TIME WITH ACCELEDENT:
10.5 MONTHS



RESULTS: 10.5 MONTHS

CASE STUDY



DEMOGRAPHICS

MALE
14 YEARS OLD

DIAGNOSIS

CLASS II
CROWDING & SPACING
DEEP BITE
EXCESSIVE OVERJET
MIDLINE DISCREPANCY
(LOWER 2MM TO LEFT)

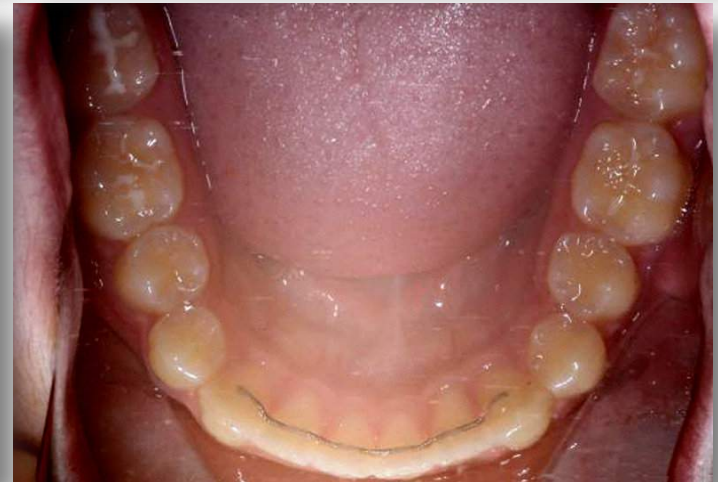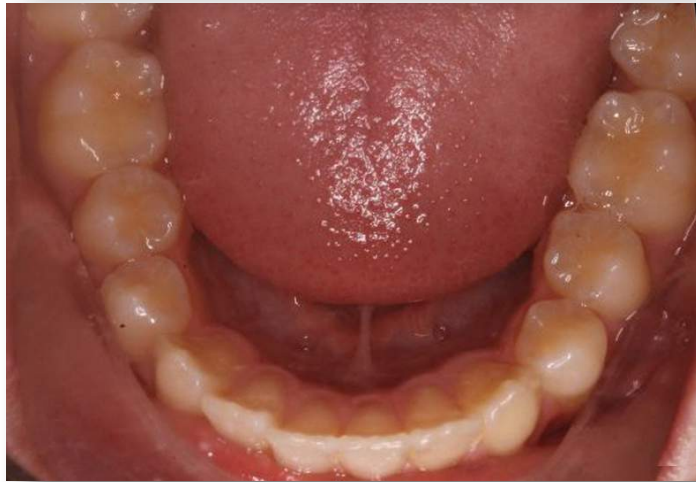
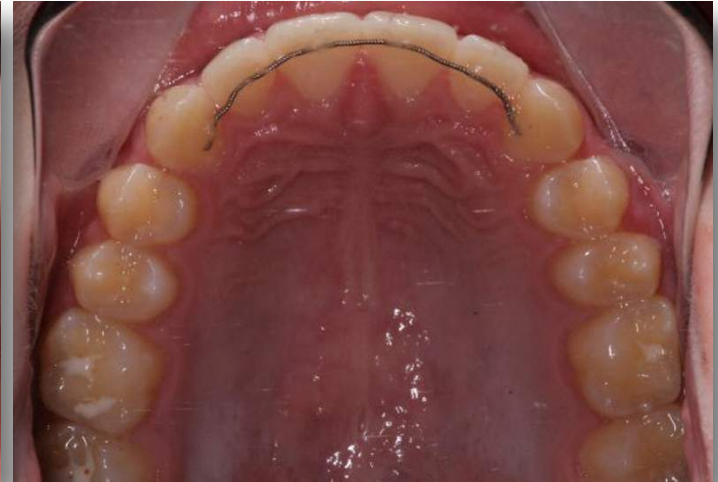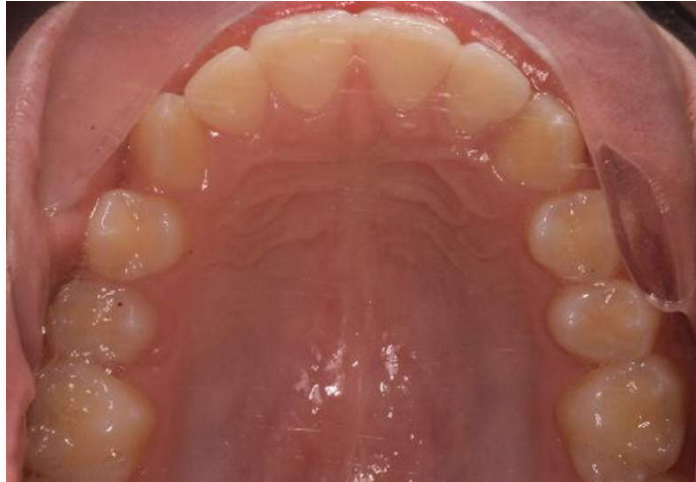MECHANICS

CARRIERE® MOTION™
INVISALIGN®
36 TOTAL ALIGNERS
NO REFINEMENT
7 DAY ALIGNER CHANGE

TREATMENT TIME

PROJECTED TREATMENT
TIME:
18 MONTHS

ACTUAL TREATMENT
TIME WITH ACCELENT:
10.5 MONTHS



RESULTS: 10.5 MONTHS

CASE STUDY



DEMOGRAPHICS

MALE
14 YEARS OLD

DIAGNOSIS

CLASS II
CROWDING & SPACING
DEEP BITE
EXCESSIVE OVERJET
MIDLINE DISCREPANCY
(LOWER 2MM TO LEFT)

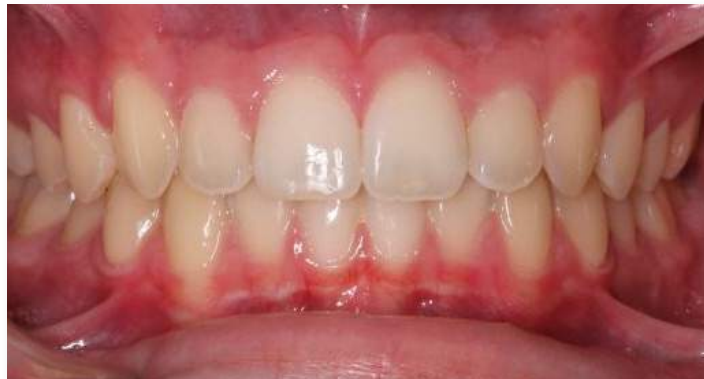
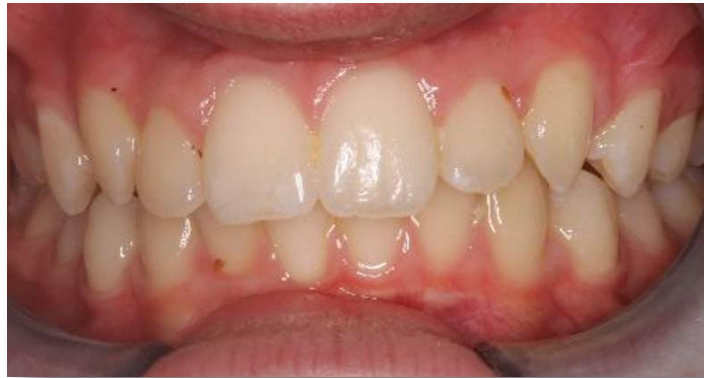MECHANICS

CARRIERE® MOTION™
INVISALIGN®
36 TOTAL ALIGNERS
NO REFINEMENT
7 DAY ALIGNER CHANGE

TREATMENT TIME

PROJECTED TREATMENT
TIME:
18 MONTHS

ACTUAL TREATMENT
TIME WITH ACCELEDENT:
10.5 MONTHS



RESULTS: 10.5 MONTHS

CASE STUDY



DEMOGRAPHICS

MALE
14 YEARS OLD

DIAGNOSIS

CLASS II
CROWDING & SPACING
DEEP BITE
EXCESSIVE OVERJET
MIDLINE DISCREPANCY
(LOWER 2MM TO LEFT)

MECHANICS

CARRIERE® MOTION™
INVISALIGN®
36 TOTAL ALIGNERS
NO REFINEMENT
7 DAY ALIGNER CHANGE

TREATMENT TIME

PROJECTED TREATMENT
TIME:
18 MONTHS

ACTUAL TREATMENT
TIME WITH ACCELEDENT:
10.5 MONTHS

