

CASE STUDY



DEMOGRAPHICS

MALE
42 YEARS OLD

DIAGNOSIS

CLASS I
SEVERE CROWDING
NARROW ARCHES
OPEN BITE
EXCESSIVE OVERJET
BLOCKED-OUT TOOTH/
TEETH
OVERJET

MECHANICS

INVISALIGN®
81 TOTAL ALIGNERS
U: 28+18+16+16+3
L: 29+19+17+15
53 REFINEMENT ALIGNERS
7 DAY ALIGNER CHANGE
ELASTICS
GINGIVAL GRAFTING

TREATMENT TIME

PROJECTED TREATMENT TIME:
30 MONTHS

ACTUAL TREATMENT TIME WITH
ACCELEDENT:
15.5 MONTHS

CASE STUDY



DEMOGRAPHICS

MALE
42 YEARS OLD

DIAGNOSIS

CLASS I
SEVERE CROWDING
NARROW ARCHES
OPEN BITE
EXCESSIVE OVERJET
BLOCKED-OUT TOOTH/
TEETH

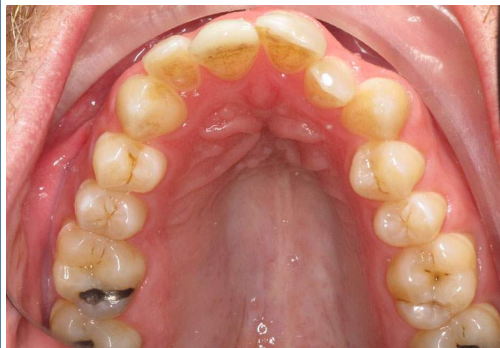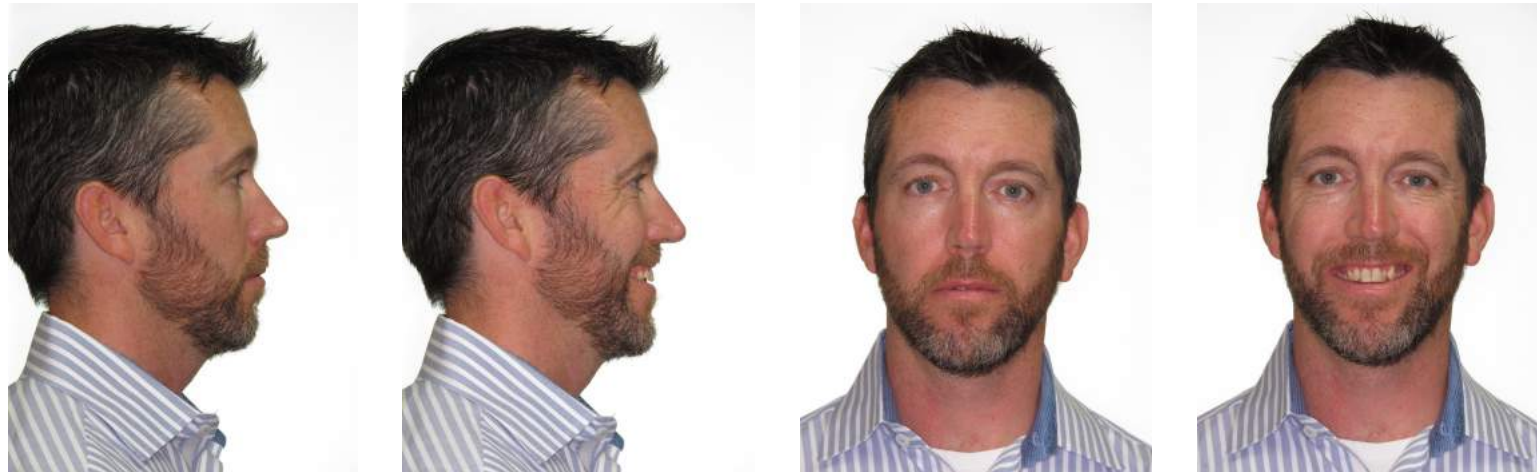MECHANICS

INVISALIGN®
81 TOTAL ALIGNERS
U: 28+18+16+16+3
L: 29+19+17+15
53 REFINEMENT ALIGNERS
7 DAY ALIGNER CHANGE
ELASTICS
GINGIVAL GRAFTING

TREATMENT TIME

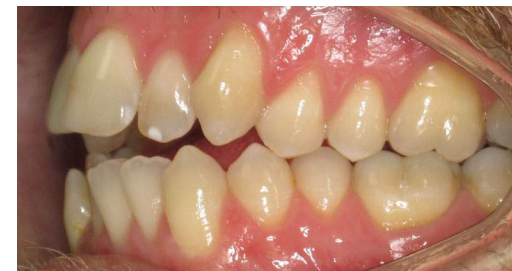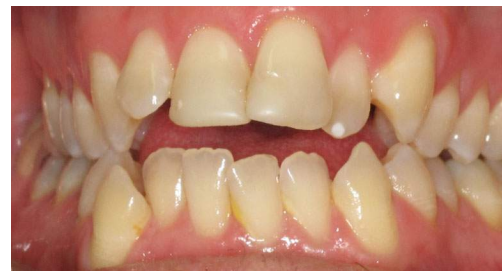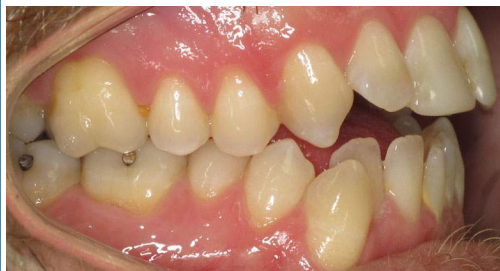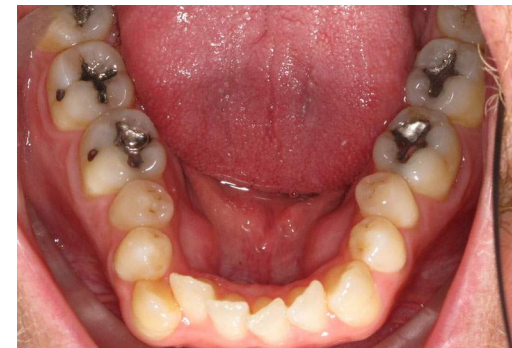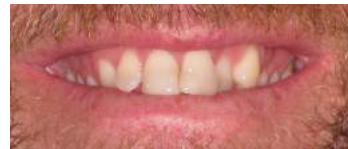PROJECTED TREATMENT
TIME:
30 MONTHS

ACTUAL TREATMENT TIME
WITH ACCELENT:
15.5 MONTHS



BASELINE

Patient Chief Concern: Anterior open bite and severe crowding



CASE STUDY



DEMOGRAPHICS

MALE
42 YEARS OLD

DIAGNOSIS

CLASS I
SEVERE CROWDING
NARROW ARCHES
OPEN BITE
EXCESSIVE OVERJET
BLOCKED-OUT TOOTH/
TEETH

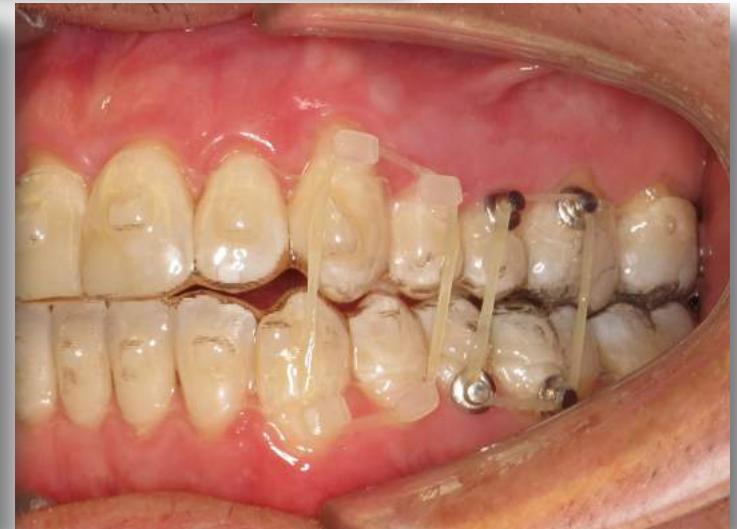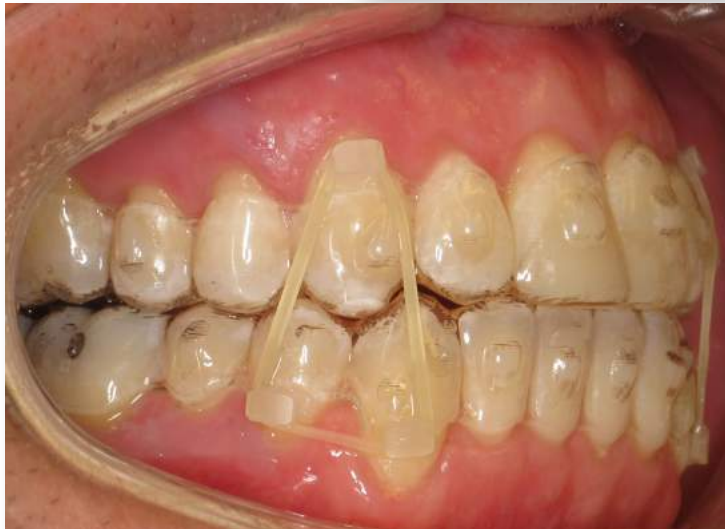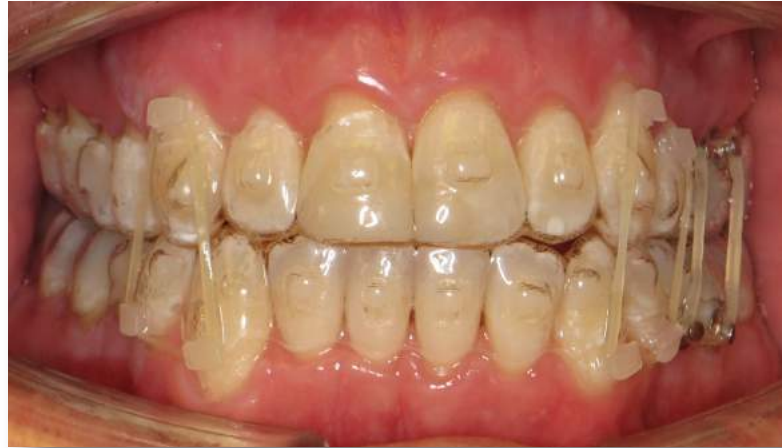MECHANICS

INVISALIGN®
81 TOTAL ALIGNERS
U: 28+18+16+16+3
L: 29+19+17+15
53 REFINEMENT ALIGNERS
7 DAY ALIGNER CHANGE
ELASTICS
GINGIVAL GRAFTING

TREATMENT TIME

PROJECTED TREATMENT
TIME:
30 MONTHS

ACTUAL TREATMENT TIME
WITH ACCELENT:
15.5 MONTHS



ELASTICS

CASE STUDY



DEMOGRAPHICS

MALE
42 YEARS OLD

DIAGNOSIS

CLASS I
SEVERE CROWDING
NARROW ARCHES
OPEN BITE
EXCESSIVE OVERJET
BLOCKED-OUT TOOTH/
TEETH

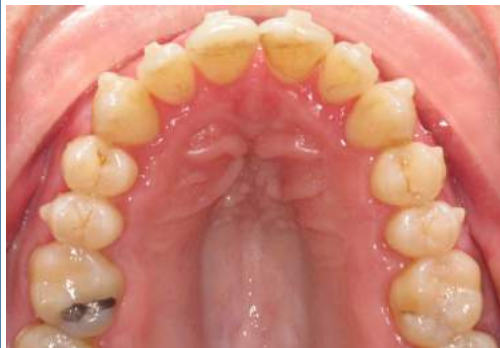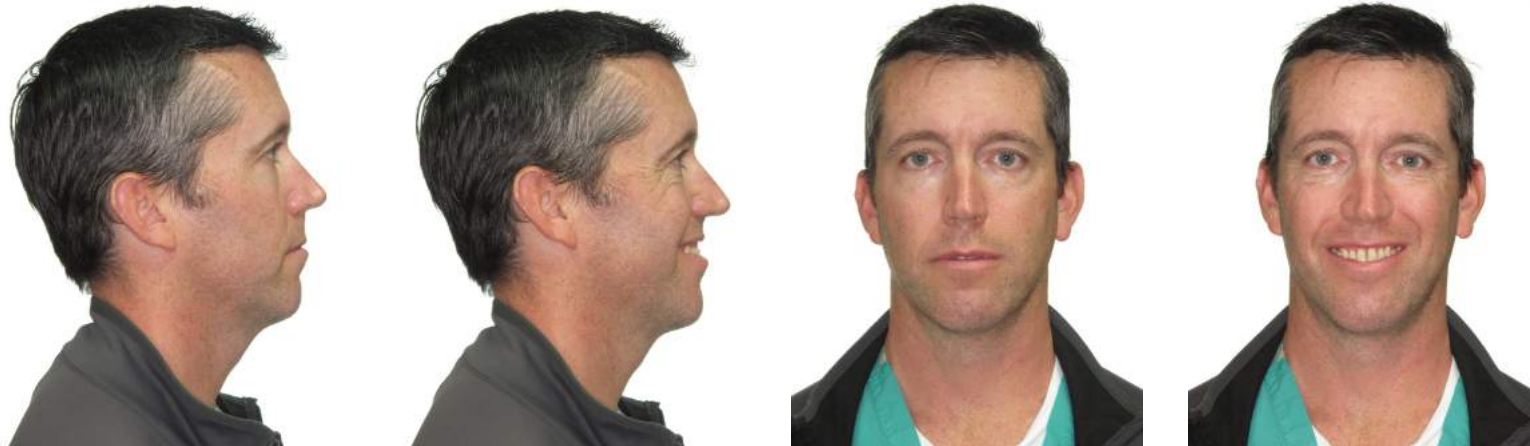MECHANICS

INVISALIGN®
81 TOTAL ALIGNERS
U: 28+18+16+16+3
L: 29+19+17+15
53 REFINEMENT ALIGNERS
7 DAY ALIGNER CHANGE
ELASTICS
GINGIVAL GRAFTING

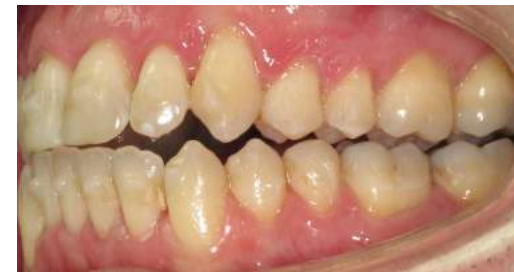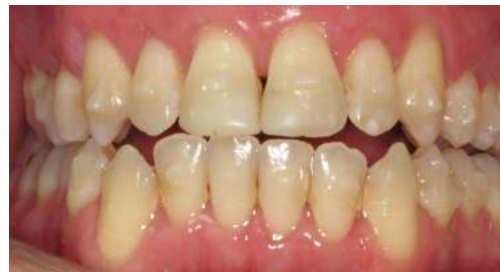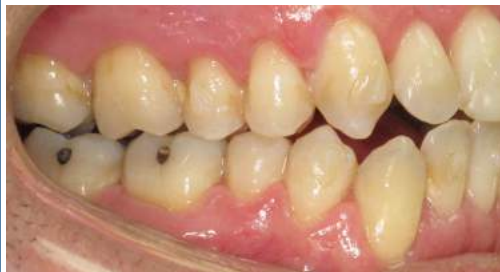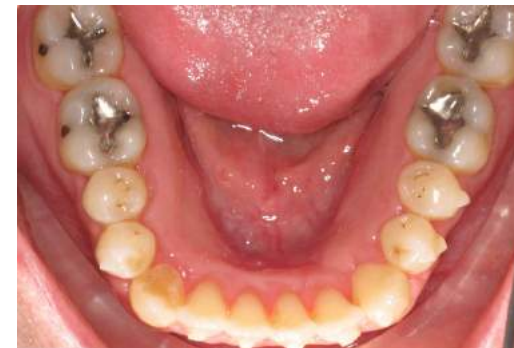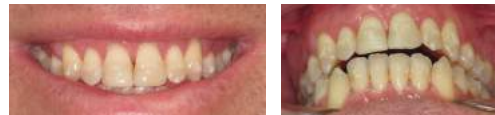TREATMENT TIME

PROJECTED TREATMENT
TIME:
30 MONTHS

ACTUAL TREATMENT TIME
WITH ACCELENT:
15.5 MONTHS



PRE-REFINEMENT



CASE STUDY



DEMOGRAPHICS

MALE
42 YEARS OLD

DIAGNOSIS

CLASS I
SEVERE CROWDING
NARROW ARCHES
OPEN BITE
EXCESSIVE OVERJET
BLOCKED-OUT TOOTH/
TEETH

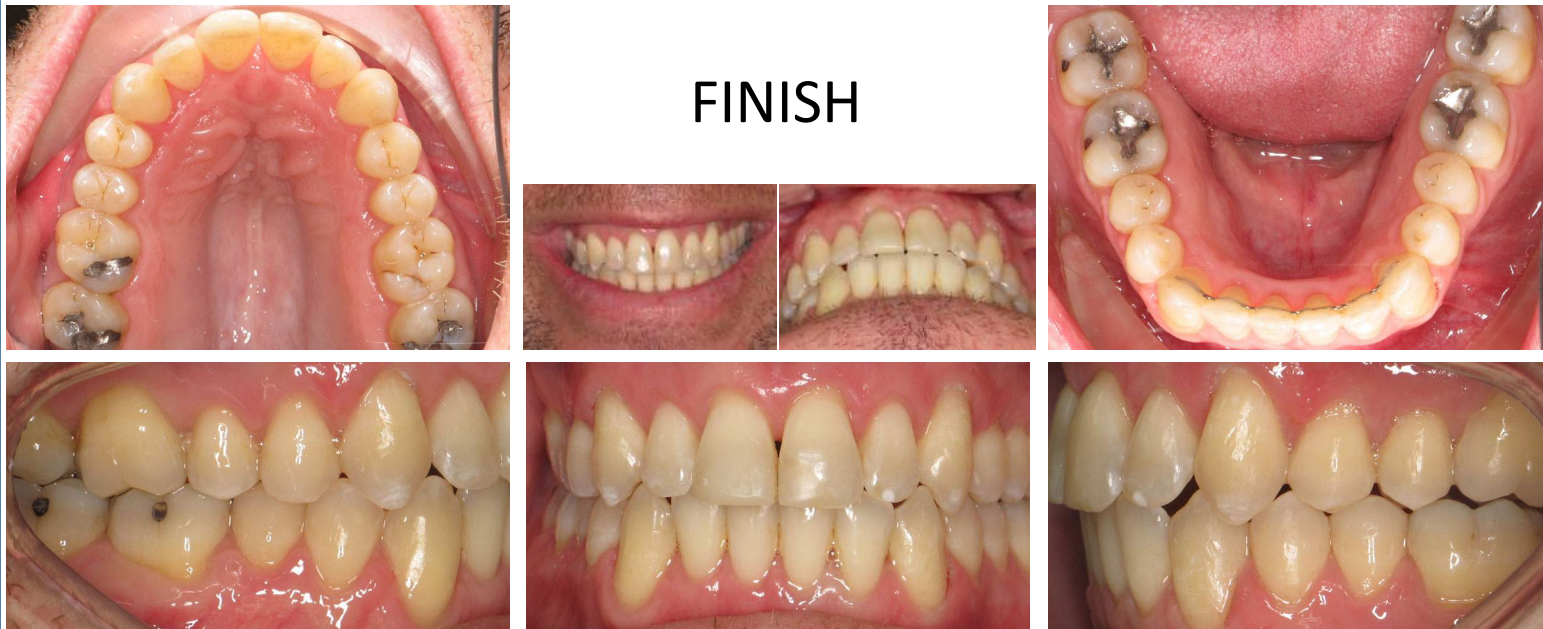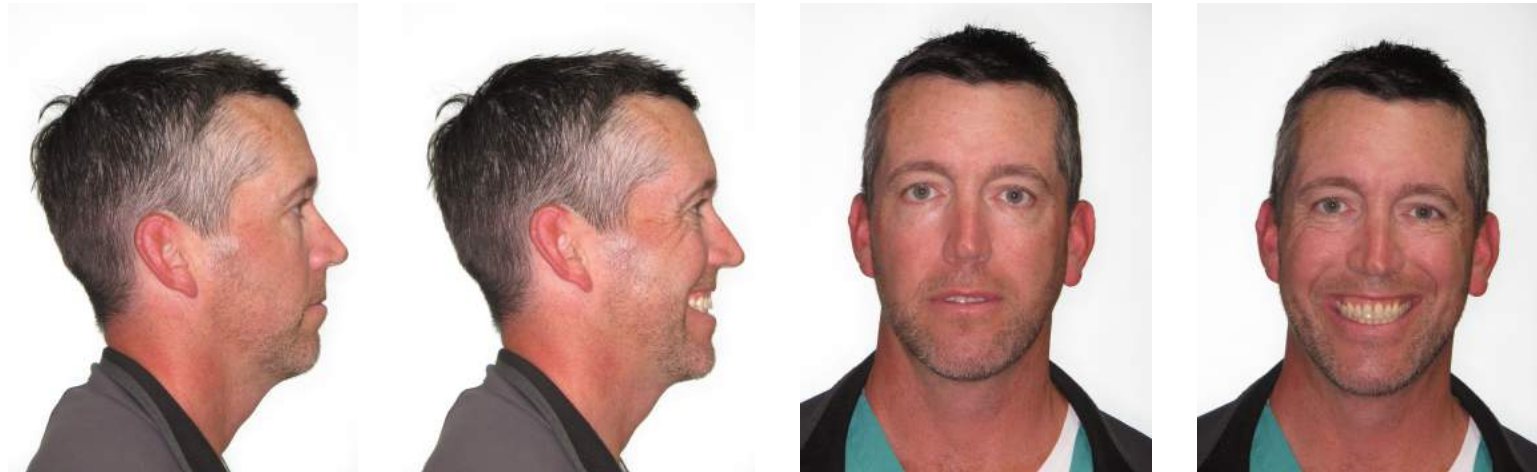MECHANICS

INVISALIGN®
81 TOTAL ALIGNERS
U: 28+18+16+16+3
L: 29+19+17+15
53 REFINEMENT ALIGNERS
7 DAY ALIGNER CHANGE
ELASTICS
GINGIVAL GRAFTING

TREATMENT TIME

PROJECTED TREATMENT
TIME:
30 MONTHS

ACTUAL TREATMENT TIME
WITH ACCELENT:
15.5 MONTHS



FINISH

CASE STUDY



DEMOGRAPHICS

MALE
42 YEARS OLD

DIAGNOSIS

CLASS I
SEVERE CROWDING
NARROW ARCHES
OPEN BITE
EXCESSIVE OVERJET
BLOCKED-OUT TOOTH/
TEETH

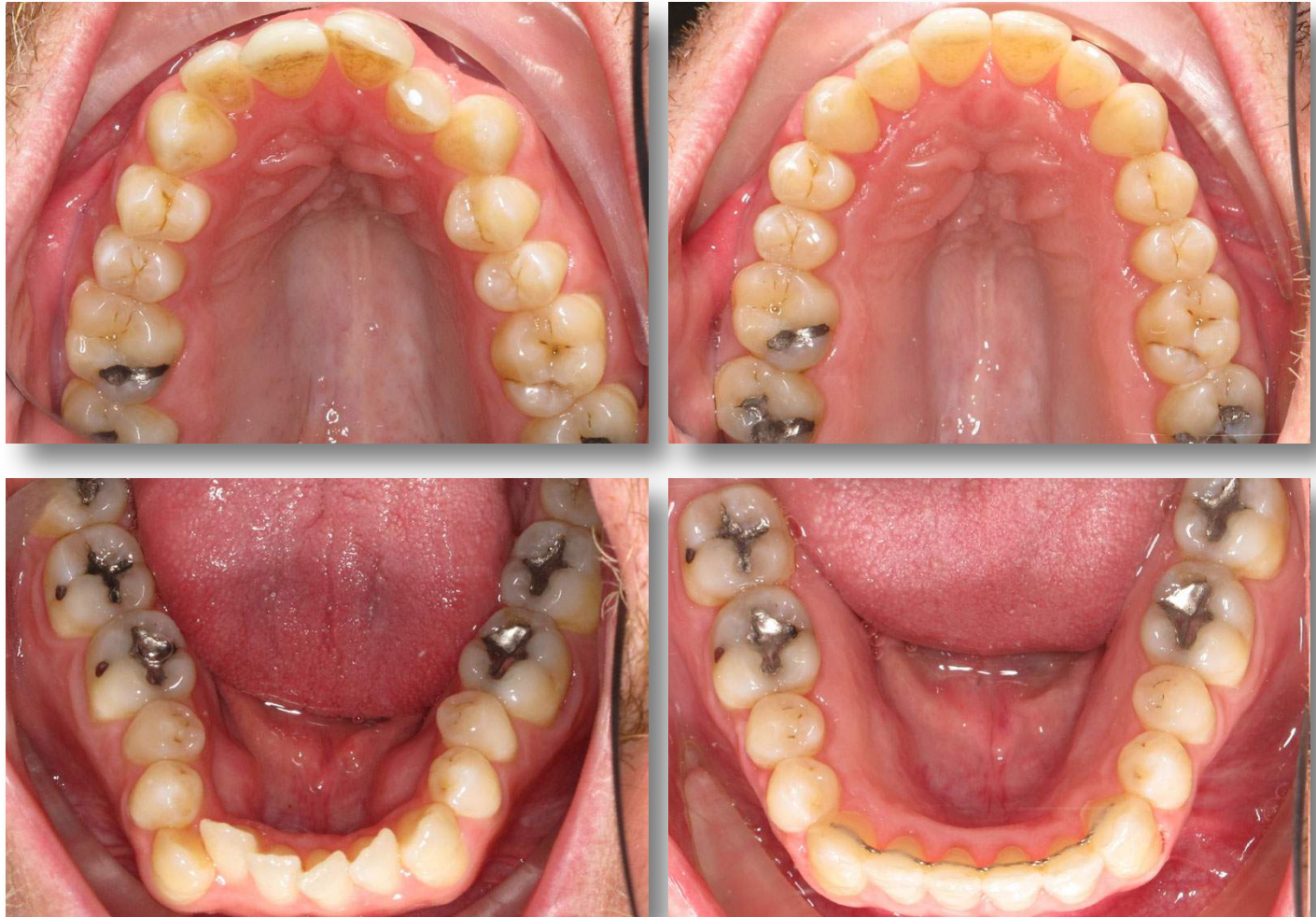
MECHANICS

INVISALIGN®
81 TOTAL ALIGNERS
U: 28+18+16+16+3
L: 29+19+17+15
53 REFINEMENT ALIGNERS
7 DAY ALIGNER CHANGE
ELASTICS
GINGIVAL GRAFTING

TREATMENT TIME

PROJECTED TREATMENT
TIME:
30 MONTHS

ACTUAL TREATMENT TIME
WITH ACCELENT:
15.5 MONTHS



RESULTS: 15.5 MONTHS

CASE STUDY



DEMOGRAPHICS

MALE
42 YEARS OLD

DIAGNOSIS

CLASS I
SEVERE CROWDING
NARROW ARCHES
OPEN BITE
EXCESSIVE OVERJET
BLOCKED-OUT TOOTH/
TEETH

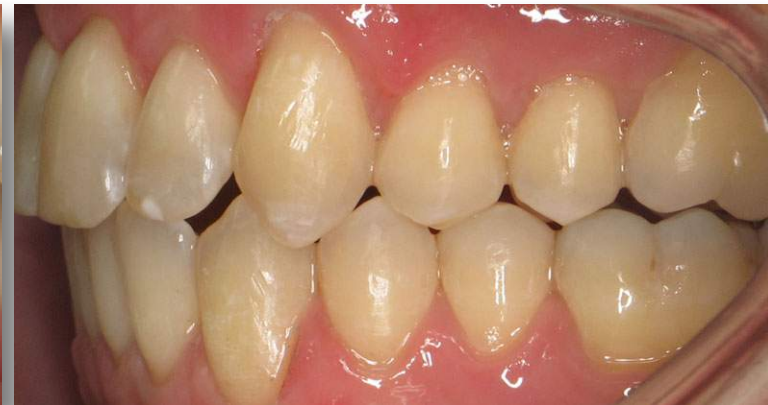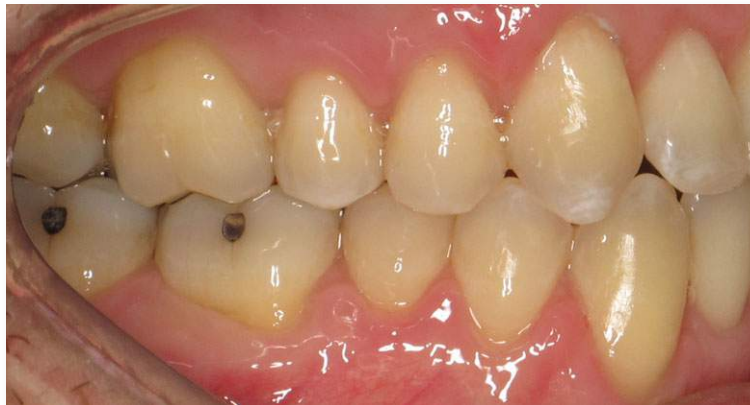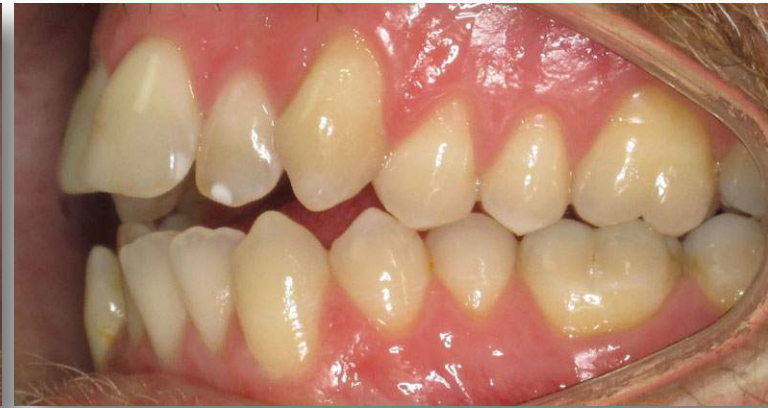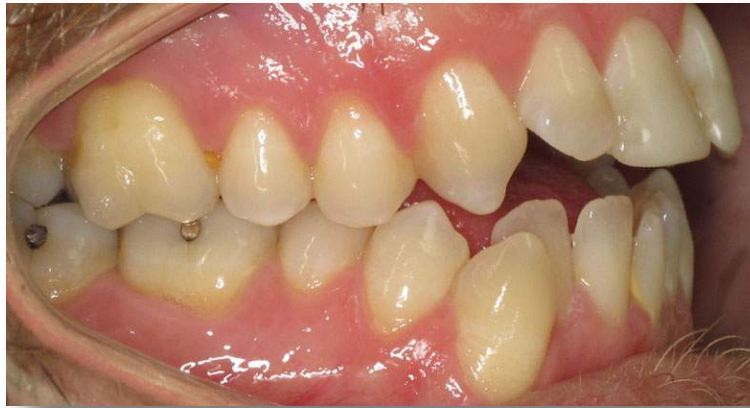MECHANICS

INVISALIGN®
81 TOTAL ALIGNERS
U: 28+18+16+16+3
L: 29+19+17+15
53 REFINEMENT ALIGNERS
7 DAY ALIGNER CHANGE
ELASTICS
GINGIVAL GRAFTING

TREATMENT TIME

PROJECTED TREATMENT
TIME:
30 MONTHS

ACTUAL TREATMENT TIME
WITH ACCELENT:
15.5 MONTHS



RESULTS: 15.5 MONTHS

CASE STUDY



DEMOGRAPHICS

MALE
42 YEARS OLD

DIAGNOSIS

CLASS I
SEVERE CROWDING
NARROW ARCHES
OPEN BITE
EXCESSIVE OVERJET
BLOCKED-OUT TOOTH/
TEETH

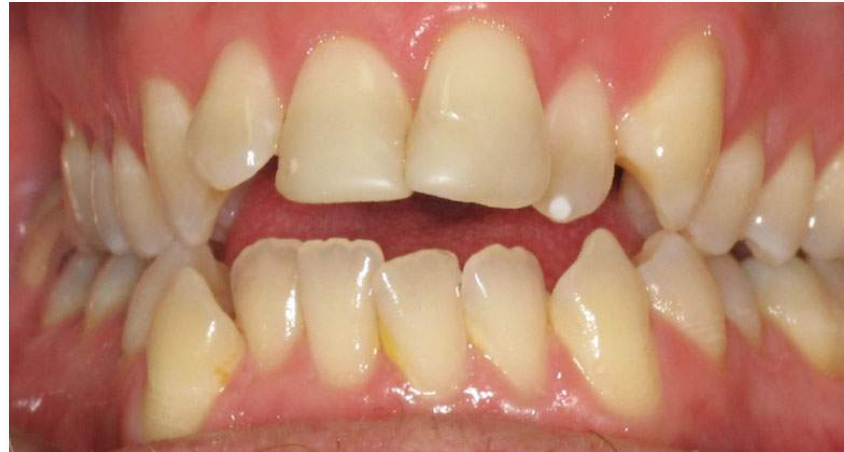MECHANICS

INVISALIGN®
81 TOTAL ALIGNERS
U: 28+18+16+16+3
L: 29+19+17+15
53 REFINEMENT ALIGNERS
7 DAY ALIGNER CHANGE
ELASTICS
GINGIVAL GRAFTING

TREATMENT TIME

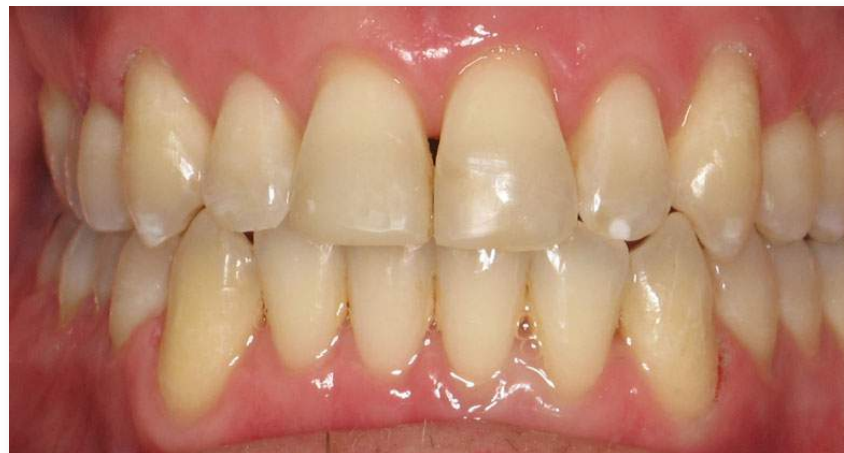PROJECTED TREATMENT
TIME:
30 MONTHS

ACTUAL TREATMENT TIME
WITH ACCELENT:
15.5 MONTHS



*A previous orthodontist had recommended surgery in addition to fixed braces. The patient finished with Invisalign and AcceleDent in a shorter time than braces, **with NO surgery.***

- Dr. Keith Sellers



RESULTS: 15.5 MONTHS

CASE STUDY



DEMOGRAPHICS

MALE
42 YEARS OLD

DIAGNOSIS

CLASS I
SEVERE CROWDING
NARROW ARCHES
OPEN BITE
EXCESSIVE OVERJET
BLOCKED-OUT TOOTH/
TEETH

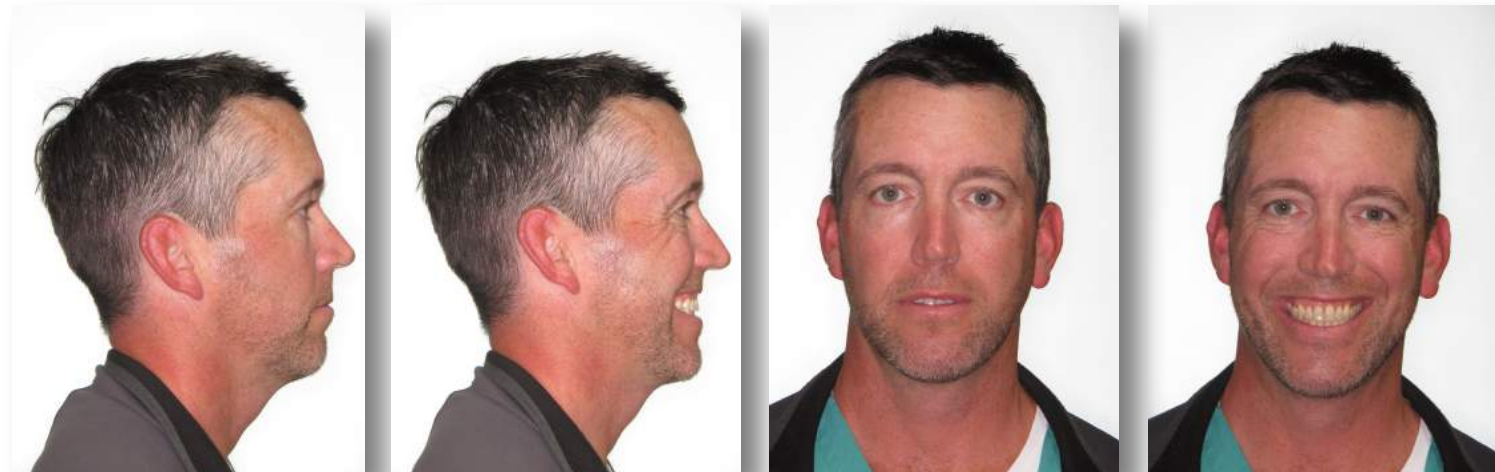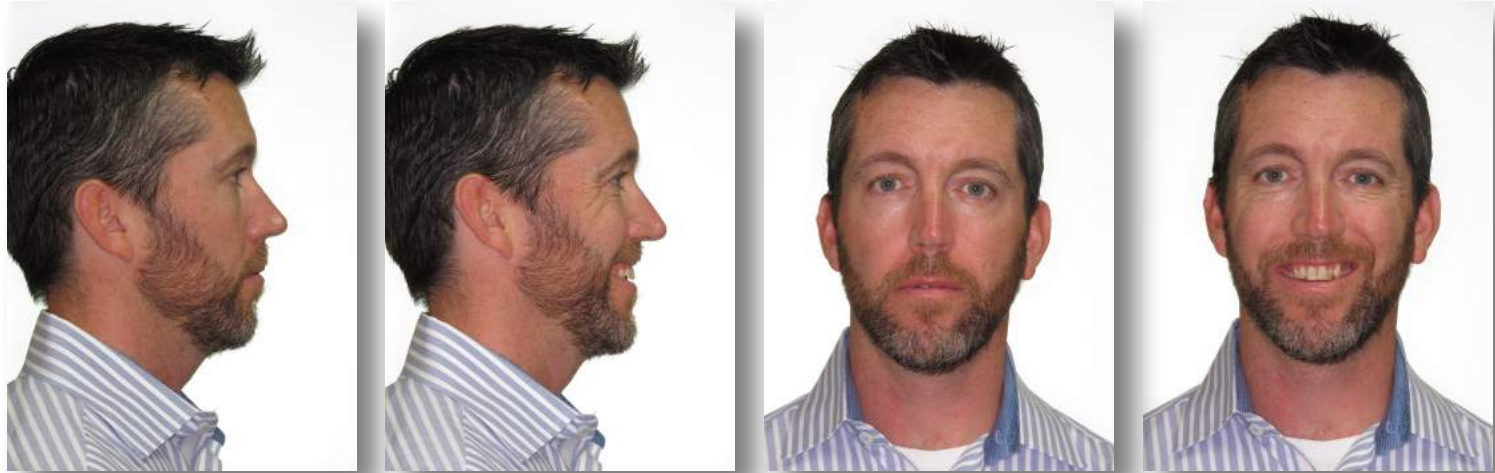MECHANICS

INVISALIGN®
81 TOTAL ALIGNERS
U: 28+18+16+16+3
L: 29+19+17+15
53 REFINEMENT ALIGNERS
7 DAY ALIGNER CHANGE
ELASTICS
GINGIVAL GRAFTING

TREATMENT TIME

PROJECTED TREATMENT
TIME:
30 MONTHS

ACTUAL TREATMENT TIME
WITH ACCELENT:
15.5 MONTHS



RESULTS: 15.5 MONTHS