

CASE STUDY



DEMOGRAPHICS	DIAGNOSIS	MECHANICS	TREATMENT TIME
FEMALE 68 YEARS OLD	CLASS I CROWDING DEEP BITE NARROW ARCHES	INVISALIGN® 63 TOTAL ALIGNERS NO REFINEMENT (AT PATIENT'S REQUEST) 3-4 DAY ALIGNER CHANGE	PROJECTED TREATMENT TIME: 14 MONTHS ACTUAL TREATMENT TIME WITH ACCELEDENT: 8 MONTHS

The patient's use of AcceleDent *"allowed the treatment to progress more rapidly to reveal that the treatment could progress toward completion without extraction as opposed to lengthy treatment only to learn that an extraction would be required, then space closure."*

- Dr. Michael Mayhew

CASE STUDY



DEMOGRAPHICS

FEMALE
68 YEARS OLD

DIAGNOSIS

CLASS I
CROWDING
DEEP BITE
NARROW ARCHES

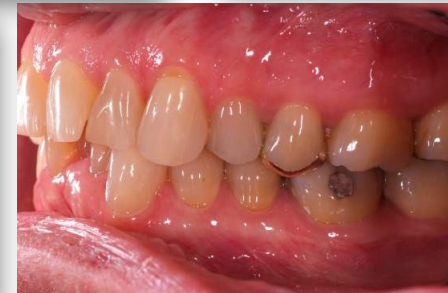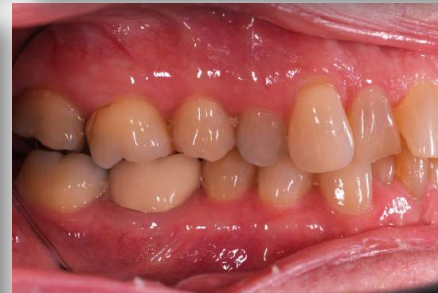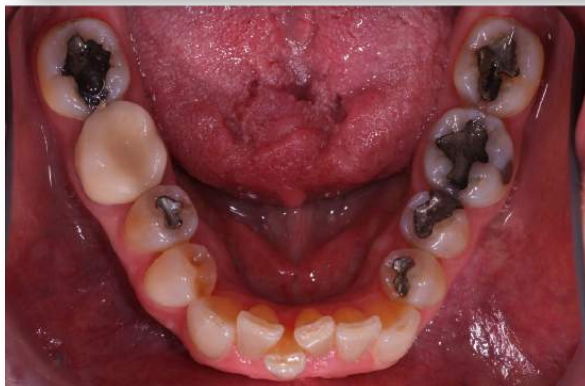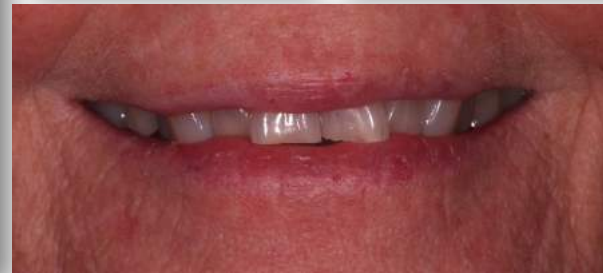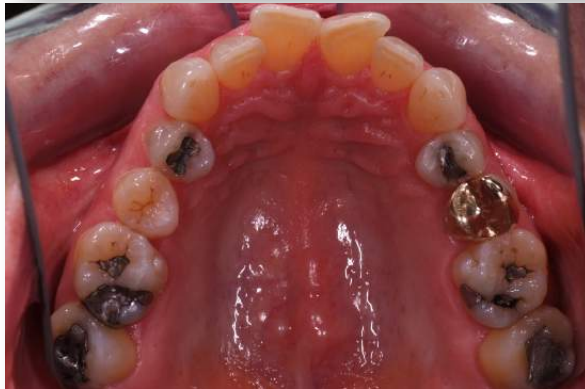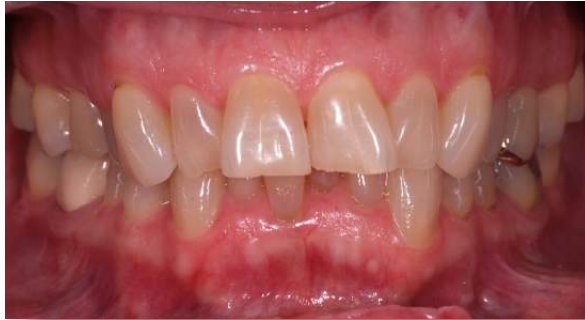MECHANICS

INVISALIGN®
63 TOTAL ALIGNERS
NO REFINEMENT (AT
PATIENT'S REQUEST)
3-4 DAY ALIGNER
CHANGE

TREATMENT TIME

PROJECTED TREATMENT
TIME:
14 MONTHS

ACTUAL TREATMENT
TIME WITH ACCELENT:
8 MONTHS



BASELINE

CASE STUDY

AcceleDent[®]
aura

DEMOGRAPHICS

FEMALE
68 YEARS OLD

DIAGNOSIS

CLASS I
CROWDING
DEEP BITE
NARROW ARCHES

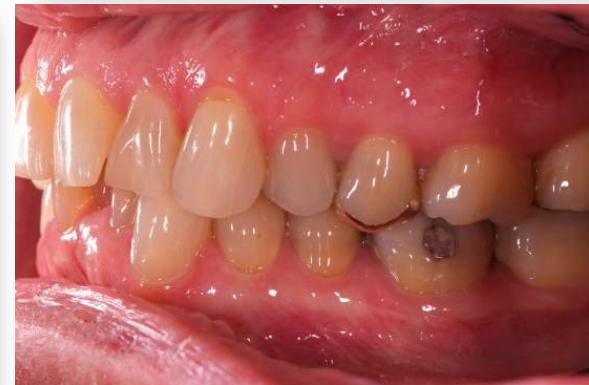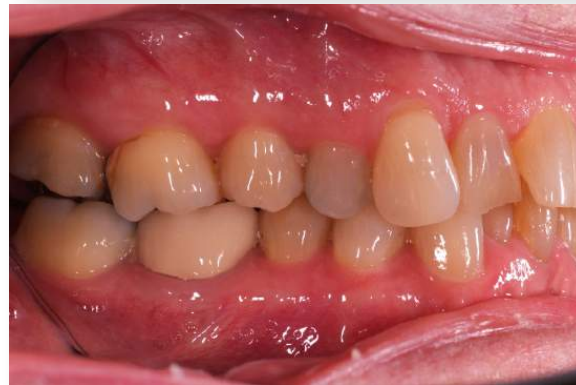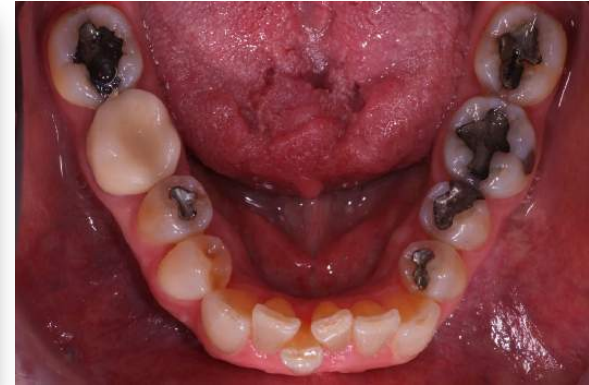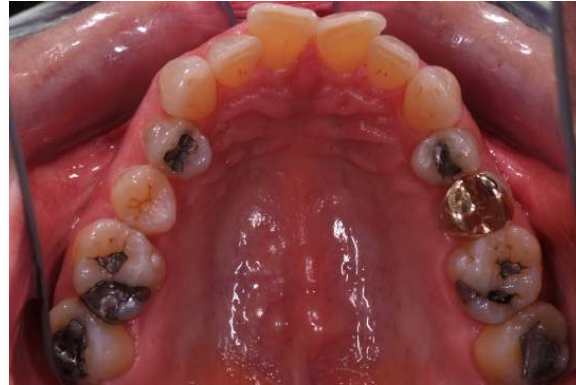MECHANICS

INVISALIGN[®]
63 TOTAL ALIGNERS
NO REFINEMENT (AT
PATIENT'S REQUEST)
3-4 DAY ALIGNER
CHANGE

TREATMENT TIME

PROJECTED TREATMENT
TIME:
14 MONTHS

ACTUAL TREATMENT
TIME WITH ACCELENT:
8 MONTHS



CHIEF CONCERN

Patient: " Lower teeth have been shifting for a long time and there is discomfort in lower teeth with chewing"

Dentist: "Concerned about alignment and stated it may be necessary to have #25 extracted to align teeth"

CASE STUDY



DEMOGRAPHICS

FEMALE
68 YEARS OLD

DIAGNOSIS

CLASS I
CROWDING
DEEP BITE
NARROW ARCHES

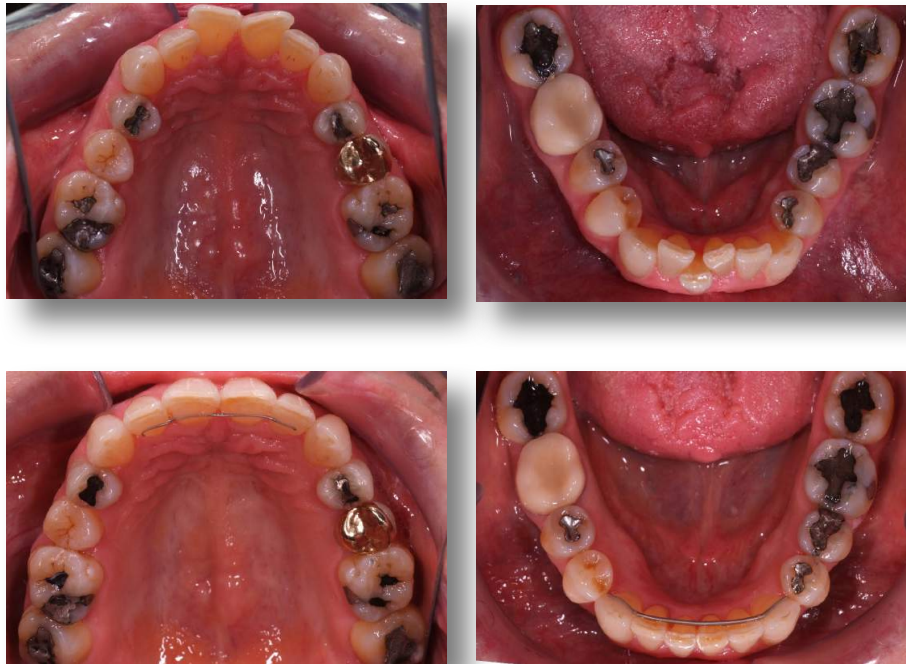
MECHANICS

INVISALIGN®
63 TOTAL ALIGNERS
NO REFINEMENT (AT
PATIENT'S REQUEST)
3-4 DAY ALIGNER
CHANGE

TREATMENT TIME

PROJECTED TREATMENT
TIME:
14 MONTHS

ACTUAL TREATMENT
TIME WITH ACCELEDENT:
8 MONTHS



The patient's use of AcceleDent "allowed the treatment to progress more rapidly to reveal that the treatment could progress toward completion **without extraction** as opposed to lengthy treatment only to learn that an extraction would be required, then space closure."

- Dr. Michael Mayhew

CLINICAL NOTES

In the ClinCheck® setup instructions Dr. Mayhew requested all arch width expansion be staged BEFORE any incisor alignment so that he had options during the treatment period to determine how feasible a non-extraction solution would be.

Dr. Mayhew requested aligner changes at 1 week intervals in the ClinCheck setup. To account for the accelerated movement anticipated with AcceleDent, he instructed the patient to change aligners every 3-4 days as she was able to properly fit the next appliance.

CASE STUDY



DEMOGRAPHICS

FEMALE
68 YEARS OLD

DIAGNOSIS

CLASS I
CROWDING
DEEP BITE
NARROW ARCHES

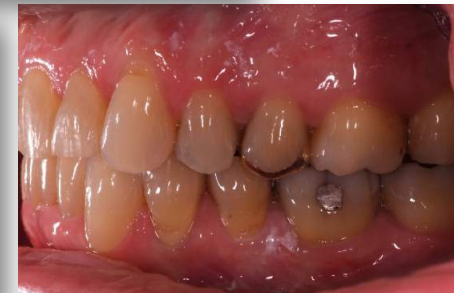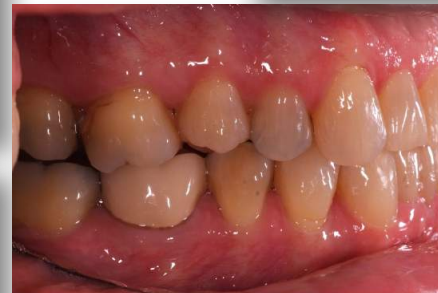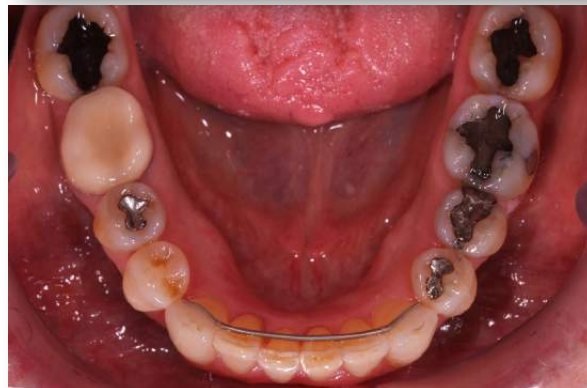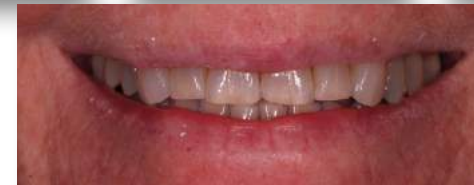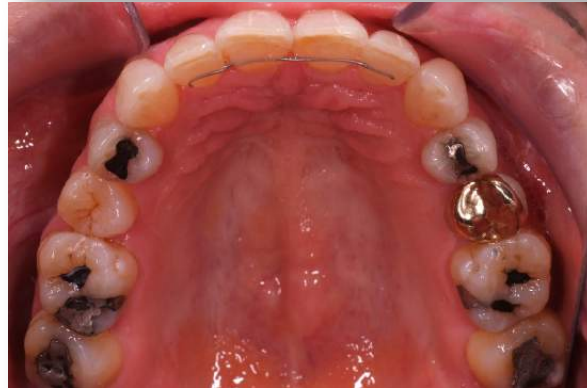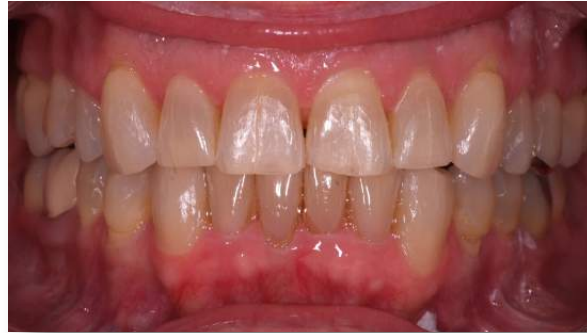MECHANICS

INVISALIGN®
63 TOTAL ALIGNERS
NO REFINEMENT (AT
PATIENT'S REQUEST)
3-4 DAY ALIGNER
CHANGE

TREATMENT TIME

PROJECTED TREATMENT
TIME:
14 MONTHS

ACTUAL TREATMENT
TIME WITH ACCELENT:
8 MONTHS



FINISH

CASE STUDY



DEMOGRAPHICS

FEMALE
68 YEARS OLD

DIAGNOSIS

CLASS I
CROWDING
DEEP BITE
NARROW ARCHES

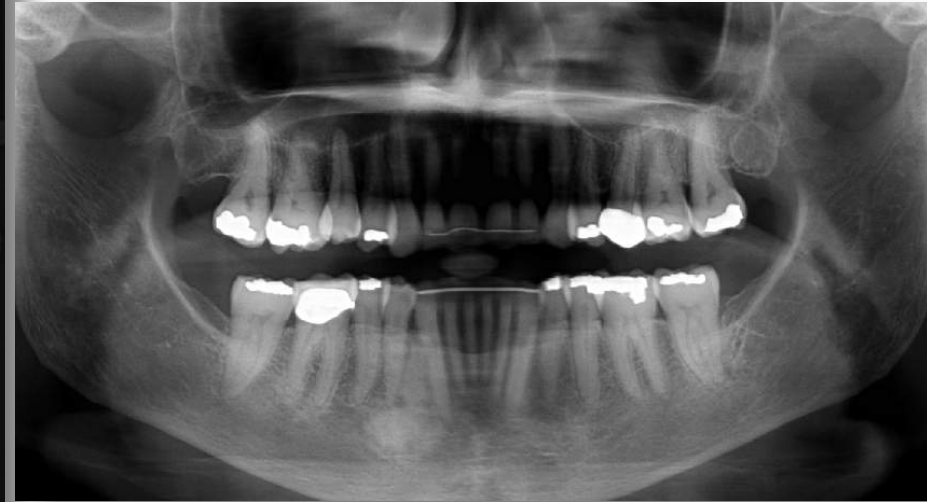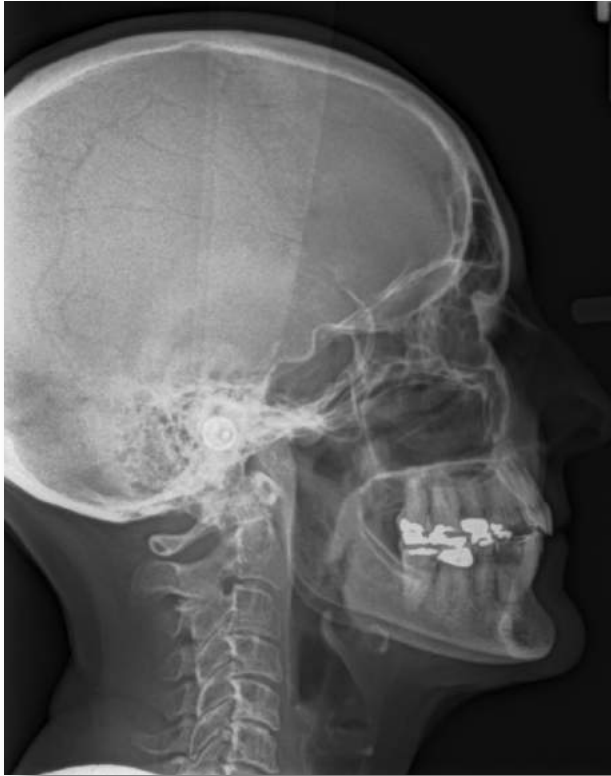MECHANICS

INVISALIGN®
63 TOTAL ALIGNERS
NO REFINEMENT (AT
PATIENT'S REQUEST)
3-4 DAY ALIGNER
CHANGE

TREATMENT TIME

PROJECTED TREATMENT
TIME:
14 MONTHS

ACTUAL TREATMENT
TIME WITH ACCELEDENT:
8 MONTHS



FINISH

CASE STUDY



DEMOGRAPHICS

FEMALE
68 YEARS OLD

DIAGNOSIS

CLASS I
CROWDING
DEEP BITE
NARROW ARCHES

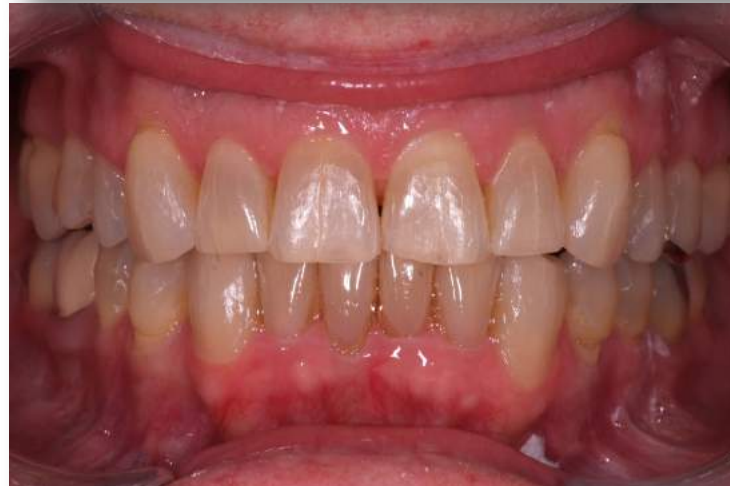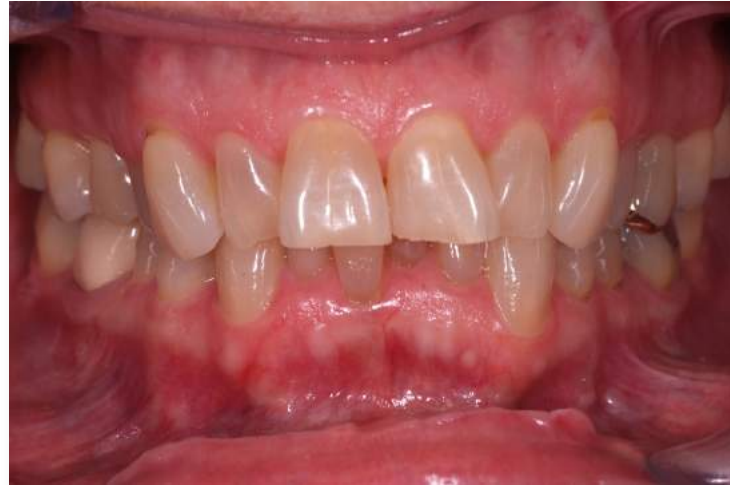MECHANICS

INVISALIGN®
63 TOTAL ALIGNERS
NO REFINEMENT (AT
PATIENT'S REQUEST)
3-4 DAY ALIGNER
CHANGE

TREATMENT TIME

PROJECTED TREATMENT
TIME:
14 MONTHS

ACTUAL TREATMENT
TIME WITH ACCELEDENT:
8 MONTHS



RESULTS: 8 MONTHS

CASE STUDY



DEMOGRAPHICS

FEMALE
68 YEARS OLD

DIAGNOSIS

CLASS I
CROWDING
DEEP BITE
NARROW ARCHES

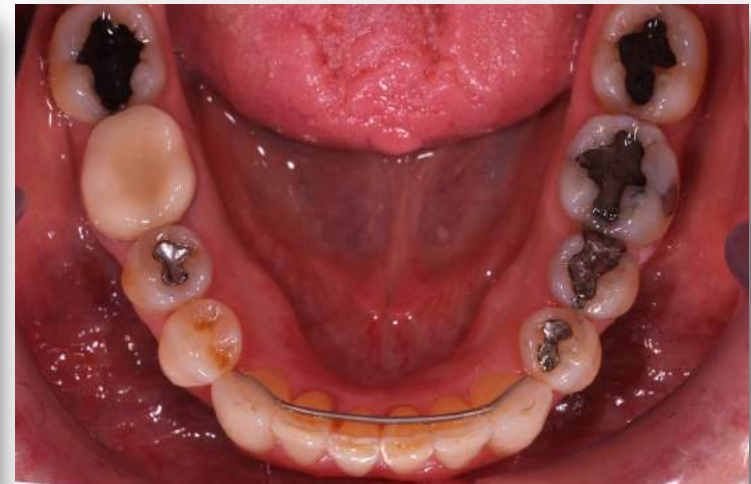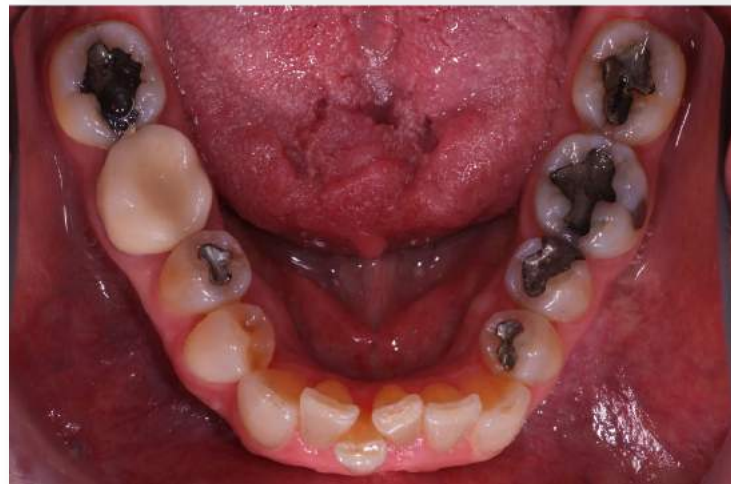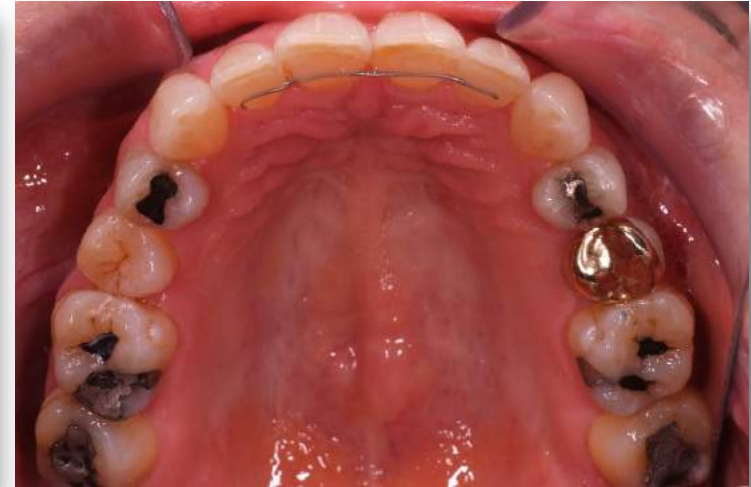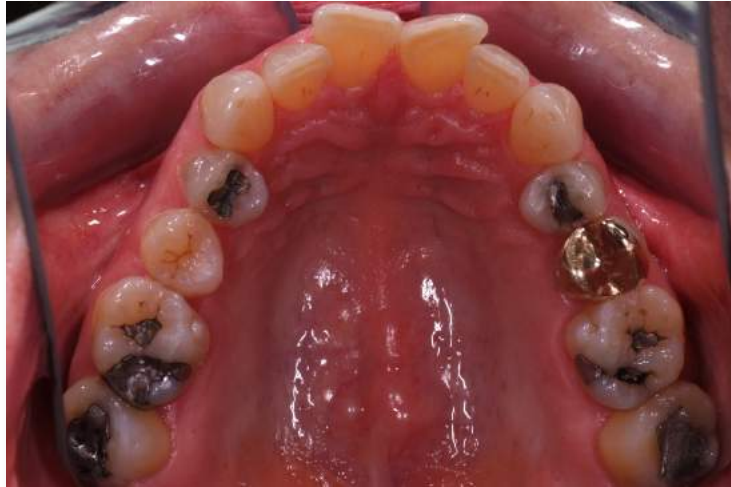MECHANICS

INVISALIGN®
63 TOTAL ALIGNERS
NO REFINEMENT (AT
PATIENT'S REQUEST)
3-4 DAY ALIGNER
CHANGE

TREATMENT TIME

PROJECTED TREATMENT
TIME:
14 MONTHS

ACTUAL TREATMENT
TIME WITH ACCELENT:
8 MONTHS



RESULTS: 8 MONTHS

CASE STUDY



DEMOGRAPHICS

FEMALE
68 YEARS OLD

DIAGNOSIS

CLASS I
CROWDING
DEEP BITE
NARROW ARCHES

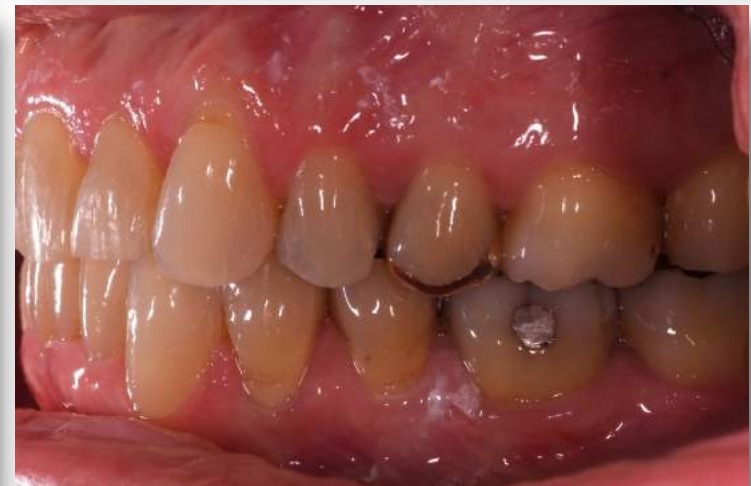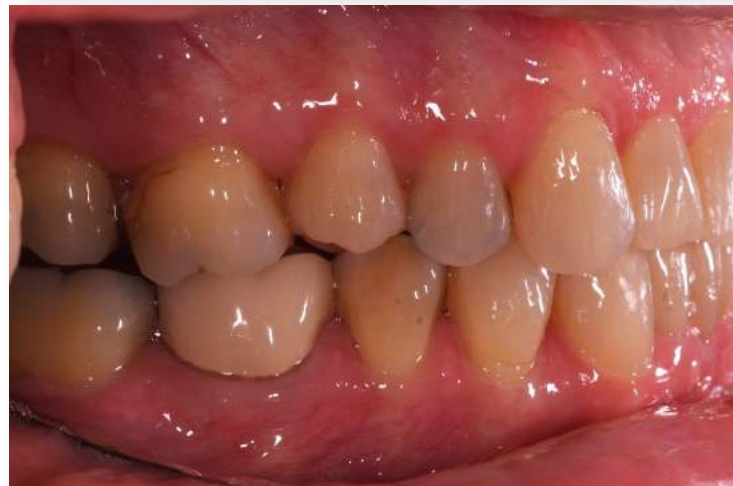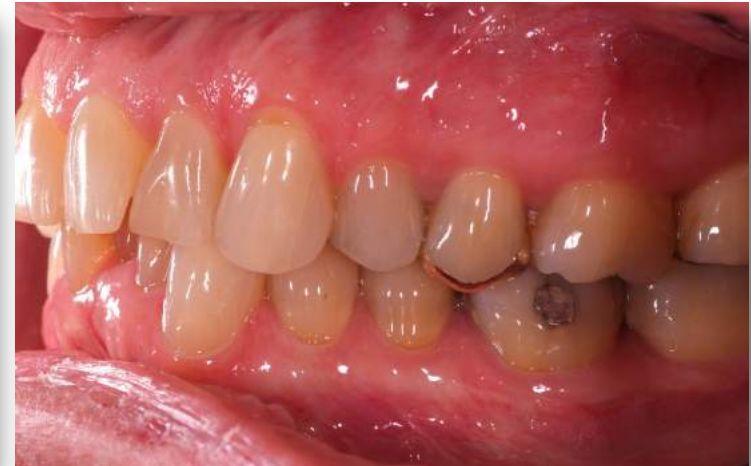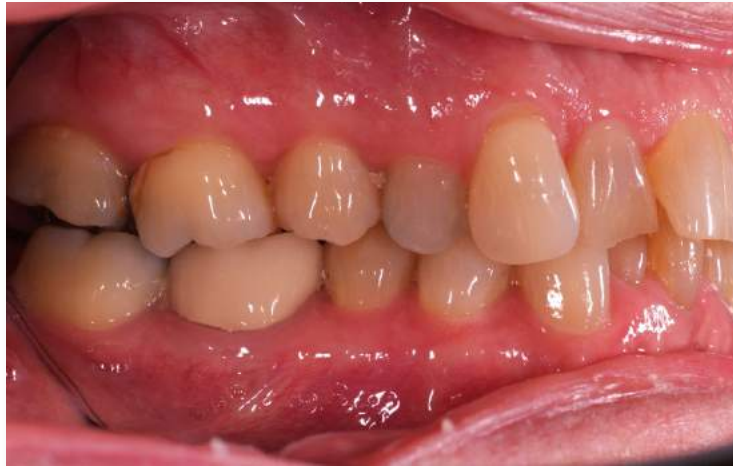MECHANICS

INVISALIGN®
63 TOTAL ALIGNERS
NO REFINEMENT (AT
PATIENT'S REQUEST)
3-4 DAY ALIGNER
CHANGE

TREATMENT TIME

PROJECTED TREATMENT
TIME:
14 MONTHS

ACTUAL TREATMENT
TIME WITH ACCELENT:
8 MONTHS



RESULTS: 8 MONTHS